



PATIENT

Paesan Marcello

PRESENTING CLINICAL SIGNS

Presented for labored breathing , pale gums, lethargy

SPECIES

Canine

BREED

Great Pyrenees

SEX

MN

AGE

3

WEIGHT

103

INTERPRETED BY

R. McKenzie Daniel,
DVM, DABVP
(Canine and Feline)

IMAGING PERFORMED BY

Jenn

HOSPITAL NAME

Rockaway Animal
Hospital

REFERRING VET

Dr Maniar

INVOICE
25048

DATE
06/09/2026

ULTRASONOGRAPHIC EXAMINATION OF THE ABDOMEN AND HEART

CANINE CARDIAC PARAMETERS	MR VMAX (m/s)	TR VMAX (m/s)	LA/AO M-mode	LA/AO (Heart Base; Swe)	FS (%)	EF (%)	EPSS (cm)
NORMAL PARAMETER	4.5-5.5	<2.7	1.3	Up to 1.6	28-40	40-100	<0.6
PATIENT	--	--	--	1.3	35	68	0.48
CANINE CARDIAC PARAMETERS	HR (BPM)	AV VMAX (m/s)	PV MAX (m/s)	BODY WEIGHT	LAD LA MAX 4 Chamber	LVIDd Avg; 2D and m-mode short axis (cm)	LVIDs Avg; 2D and m-mode short axis (cm)
NORMAL PARAMETER	50-100	0.7-1.7	0.7-1.6				
PATIENT	NM	1.3	1.1	103	4.3	4.7	--

Cardiac Presentation

The echocardiogram in this patient demonstrated normal left atrial size based on 2 separate methods of LA evaluation. The cranial and caudal mitral valve leaflets presented normal linear structure, extension in systole, and union in diastole with normal kinesis. No overt MR on Doppler. The left ventricle presented thicknesses with linear contour and was not dilated nor restricted. The myocardium presented normal echogenicity without subjective evidence of significant fibrotic or ischemic disease. Contractility of the ventricular walls was adequate and in normal range for this patient evidenced by the fractional shortening measurement and subjective evaluation of the different regions of the myocardium. The left ventricular outflow tract demonstrated normal laminar flow and subjective structural integrity. Normal measured LVOT velocity. The right atrium and auricle revealed normal size, structure and content. No evidence of masses was noted. Tricuspid valvular assessment demonstrated adequate linear morphology and kinesis. No overt TR on Doppler. The right ventricle was of normal size (1/3 diameter of LV), chordae structure, myocardial echogenicity and thickness. Pulmonary outflow tract assessment revealed normal valve structure, laminar flow, and diameter (approx.1:1 pa/ao ratio). Minor pulmonic valve insufficiency. Normal measured RVOT velocity. No visible pericardial or free pleural fluid was noted. The cranial mediastinum and pericardial and extra-cardiac regions were free of masses in the visible window. No evidence of arrhythmia.

Urinary System

The urinary bladder, trigone, cystourethral junction, and visible pelvic urethra to a depth of 3 cm exhibited normal thickness and tone. Anechoic urine was present in the lumen with no evidence of urine/lumen sediment, mineral, or calculi. The ureteral papillae were normal. The ureters were not visible which is normal. No evidence of inflammatory or neoplastic changes was noted.



PATIENT

The residual prostate appeared normal and free of pathology

Paesan Marcello

Normal size and margination were present in the kidneys. A normal 1:3 cortex / medulla ratio and normal corticomedullary definition were maintained. The echogenicity of the cortex was similar to or slightly less than normal liver parenchyma while the medulla echogenicity was hypoechoic to the cortex with no evidence of pelvic dilation. The left kidney measured 6.9 cm in length. The right kidney measured 6.8 cm in length.

SPECIES

Canine

The area of the aortic trifurcation was free of pathology.

BREED

Adrenal Glands

Great Pyrenees

The left adrenal gland was uniform in size and contour with a uniformly hypoechoic parenchyma. The left adrenal gland measured 0.51 cm width at the caudal pole. The right adrenal gland was not definitively visualized, no overt pathology in the area of the right adrenal gland.

SEX

Spleen

MN

The spleen exhibited a finely textured and homogenous parenchyma which was hyperechoic to the liver and renal cortical parenchyma. The capsule was smooth and regular without apparent expansion. The splenic vasculature at the hilus was normal in volume with no evidence of congestion or thrombosis. Acute to chronic inflammatory, neoplastic, or benign parenchyma changes were not noted.

AGE

3

WEIGHT

Liver/Gallbladder

103

The liver was subjectively normal in size, structure, and contour. The liver parenchyma was uniform and hypoechoic to the spleen with a mild coarse echotexture. Normal vascular volume. The hepatic and portal vasculature were normal in appearance without signs of congestion. The gallbladder was non-distended in size with thin walls and primarily anechoic luminal content. The cystic and common bile ducts were normal.

INTERPRETED BY

R. McKenzie Daniel,
DVM, DABVP
(Canine and Feline)

Gastrointestinal

The stomach presented intact wall layering with a normal wall layer ratio. The lumen of the stomach was empty with no signs of ileus, obstruction or foreign material.

IMAGING PERFORMED BY

Jenn

The small intestine presented intact wall layering with 1:3 muscularis/mucosa ratio. The lumen of the small intestine was empty with no signs of mechanical/metabolic ileus, obstruction or foreign material.

HOSPITAL NAME

Rockaway Animal
Hospital

Normal visible colon wall layers were present with apparent formed feces in lumen.

Pancreas

The parenchyma of the left limb, body and right limb of the pancreas presented isoechoic to the adjacent omental fat. A normal curvilinear capsule contour of the pancreas was present. The visible pancreatic duct was normal. No signs of active inflammation or neoplastic disease was evident.

REFERRING VET

Dr Maniar

Free Abdomen

No omental masses, overt lymphadenopathy or peritoneal effusion was present.

INVOICE 25048

ULTRASONOGRAPHIC FINDINGS

DATE

06/09/2026



PATIENT

Primary

Paesan Marcello

- Normal cardiac structure / function
- Minor pulmonic valve insufficiency- not considered hemodynamically significant
- Sonographically unremarkable abdomen

SPECIES

Canine

INTERPRETATION OF THE FINDINGS & FURTHER RECOMMENDATIONS

BREED

Great Pyrenees

No evidence of structural /functional cardiomyopathy or sonographically evident abdominal visceral pathology as a cause of the patient's clinical history. Correlation with full lab work, UA, 3 view chest radiographs and if evidence of anemia, CBC pathology review is recommended. A screening cortisol level may be considered if clinically indicated.

SEX

MN

AGE

3

WEIGHT

103

INTERPRETED BY

R. McKenzie Daniel,
DVM, DABVP
(Canine and Feline)

IMAGING PERFORMED BY

Jenn

HOSPITAL NAME

Rockaway Animal
Hospital

REFERRING VET

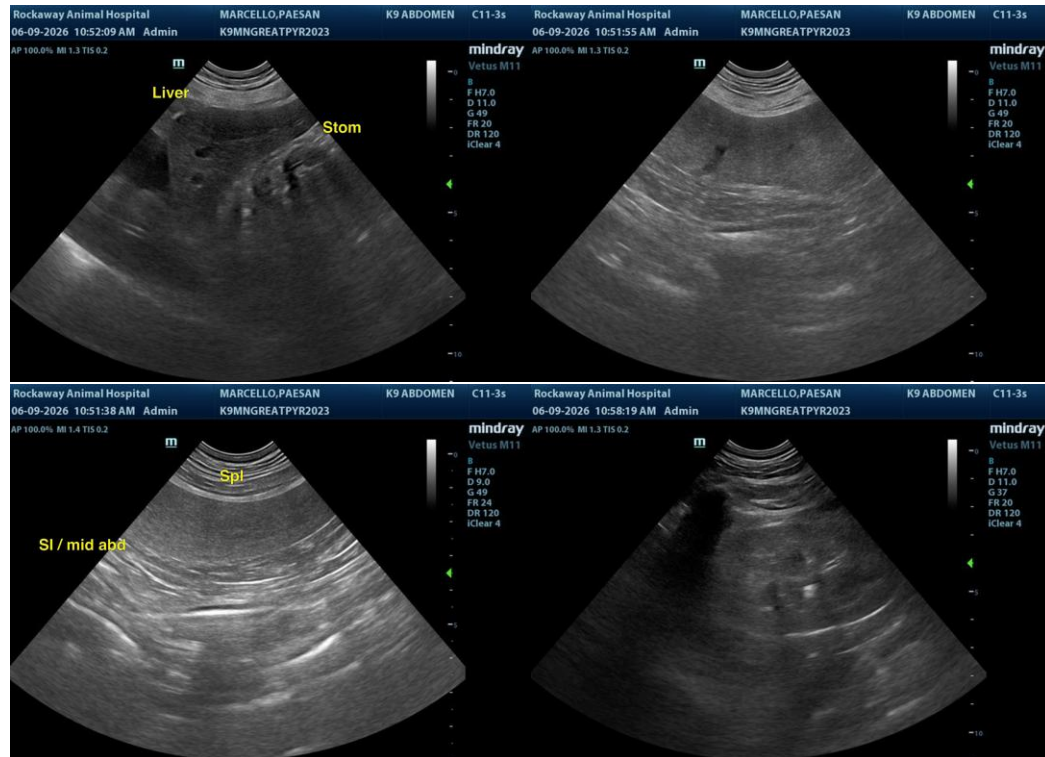
Dr Maniar

INVOICE

25048

DATE

06/09/2026





PATIENT

Paesan Marcello

SPECIES

Canine

BREED

Great Pyrenees

SEX

MN

AGE

3

WEIGHT

103

INTERPRETED BY

R. McKenzie Daniel,
DVM, DABVP
(Canine and Feline)

IMAGING PERFORMED BY

Jenn

HOSPITAL NAME

Rockaway Animal
Hospital

REFERRING VET

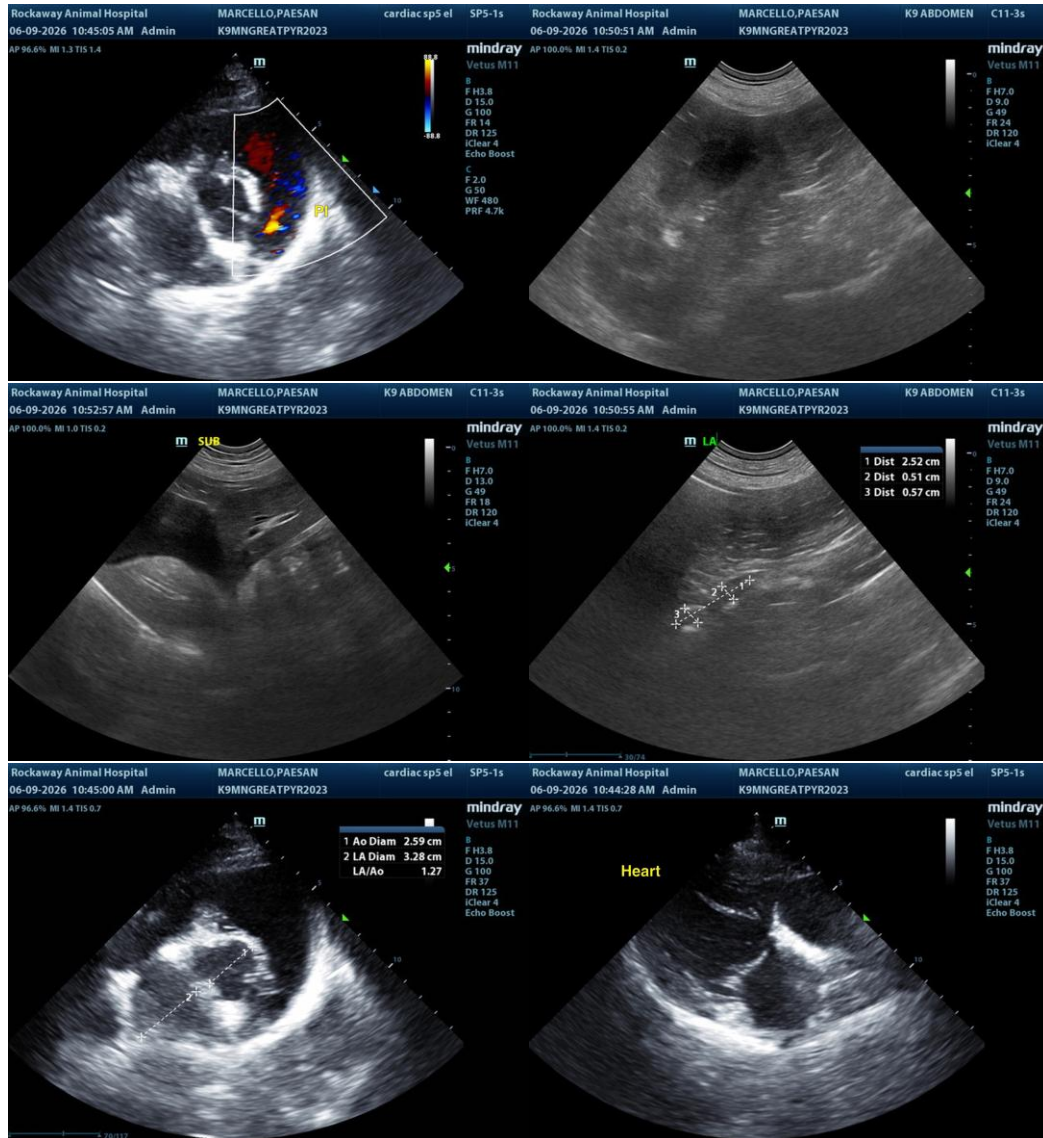
Dr Maniar

INVOICE

25048

DATE

06/09/2026



The information and recommendations provided are based on the images presented by the referring veterinarian/sonographer. No evaluation can be communicated regarding pathology that was not visible in the image/video clips provided.

Thank you for this referral. If the clinical or image interpretation does not parallel your findings or if I can be of any further assistance, please contact me.

R. McKenzie Daniel, DVM, DABVP (Canine/Feline Practice)
info@sonopath.com